



## ESTUDIO ORIGINAL: ESTUDIO OBSERVACIONAL

### Congenital Anomalies of the Nose: retrospective study and literature review

Anomalías congénitas nasales: Estudio retrospectivo y revisión de la literatura.

Carlos Fernando Ríos-Deidán<sup>1</sup>, Edgar Vinicio Escalante-Fiallos<sup>2</sup>, Mercedes Narváez-Black<sup>3</sup>, Karen Sofía Flores-Mena<sup>4</sup>, Tamara Michelle Acosta-Castillo<sup>5</sup>

CAMBios. 2022, v.21 (1): e828

Received: 2022-06-06 Approved: 2022-06-08 Published: 2022-06-30

<sup>1</sup>Central University of Ecuador, Otorhinolaryngology Department of Medical Sciences Faculty, Carlos Andrade Marín Specialties Hospital, Otorhinolaryngology Unit. Quito-Ecuador.  
deidancar@hotmail.com  
ORCID: <https://orcid.org/0000-0001-6120-0004>.

<sup>2</sup>Carlos Andrade Marín Specialties Hospital, Otorhinolaryngology Unit. Quito-Ecuador.  
gato-evef@hotmail.com  
ORCID: <https://orcid.org/0000-0001-6668-3471>

<sup>3</sup>Central University of Ecuador, Otorhinolaryngology Department of Medical Sciences Faculty, Carlos Andrade Marín Specialties Hospital, Otorhinolaryngology Unit. Quito-Ecuador.  
mechitanarvablack@gmail.com  
ORCID: <https://orcid.org/0000-0003-5170-0703>

<sup>4</sup>Carlos Andrade Marín Specialties Hospital, Otorhinolaryngology Unit. Quito-Ecuador.  
karen15\_floresm@hotmail.com  
ORCID: <https://orcid.org/0000-0002-2789-2067>

<sup>5</sup>Eugenio Espejo Specialties Hospital, Otorhinolaryngology Unit. Quito-Ecuador.  
tamaracosta1993@gmail.com  
ORCID: <https://orcid.org/0000-0002-5400-4336>

#### Author correspondence:

Dr. Carlos Fernando Ríos Deidán.

Street Alonso Martín Oe901 and Hernán Vásquez, Urbanización, Iñaquito Alto. Quito-Ecuador

Postal Code: 170527

Telephone: (593) 987429840

Copyright: ©HECAM

#### ABSTRACT

**INTRODUCTION.** Congenital malformations occur in 1 in 5,000 to 40,000 live births. They present as a morphological abnormality of the nasal pyramid or as a picture of moderate to severe nasal obstruction. **OBJECTIVE.** Evaluate the etiology, associated comorbidities, management and mortality of congenital malformations of the nose in neonates and infants. **MATERIALS AND METHODS.** Cross-sectional retrospective descriptive study, 105 medical records were reviewed, of which 26 corresponded to patients with congenital nasal malformations, at the Carlos Andrade Marín Specialty Hospital in Quito - Ecuador, between January 2009 and May 2022; the tabulation and analysis of data was carried out in the Excel program. The patients were classified according to Losee et al. in 4 types: hypoplasia, hyperplasia, clefts and tumors **RESULTS.** Nasal anomalies occurred in males in 73.07%, all presented nasal obstruction, the diagnosis was made by flexible nasofibroscope; in 42.3% of the cases, the evaluation was complemented with computed tomography. The most frequent congenital pathology was stenosis - choanal atresia with 53.8%, followed by craniofacial clefts with 15.39%. In 42.3% of the cases there was an association with genetic syndromes, neurological, ocular and intestinal pathology. 69.23% of the patients received clinical treatment with nasal lavages, nasal corticosteroids and positive pressure by cannula, while 30.77% were resolved surgically, being: 2 unilateral choanal atresia, 1 middle fossa stenosis, 4 cleft lip and palate and 1 encephalocele. Mortality was 7.69% **CONCLUSION.** Hypoplasias and clefts are the predominant pathologies, flexible nasal nasofibroscope is the diagnostic test of choice. The clinical treatment was successful in the initial management in 69.23% of cases. Surgery was performed for the repair of facial clefts; being the hypoplasias or masses managed by endoscopic approach.

**Keywords:** Nasal Obstruction; Endoscopy; Congenital Abnormalities; Choanal Atresia; Nose Diseases; Infant newborn.

#### RESUMEN

**INTRODUCCIÓN.** Las malformaciones congénitas se presentan en 1 de cada 5.000 a 40.000 nacidos vivos. Se presentan como una anomalía morfológica de la pirámide nasal o como un cuadro de obstrucción nasal moderada a severo. **OBJETIVO.** Evaluar la etiología, comorbilidades asociadas, manejo y mortalidad de las malformaciones congénitas de nariz en neonatos y lactantes. **MATERIALES Y MÉTODOS.** Estudio descriptivo retrospectivo transversal, se revisaron 105 historias clínicas de las cuales 26 correspondieron a pacientes con malformaciones congénitas nasales, en el Hospital de Especialidades Carlos Andrade Marín de Quito - Ecuador, entre enero de 2009 a mayo de 2022; la tabulación y análisis de datos se realizó en el programa Excel. Los pacientes fueron clasificados según Losee et al. en 4 tipos: hipoplasia, hiperplasia, hendiduras y tumores. **RESULTADOS.** Las anomalías nasales se presentaron en el sexo masculino en el 73.07%, el motivo de consulta fue la obstrucción nasal, el diagnóstico se realizó mediante nasofibroscofia flexible; en el 42,3% de los casos se complementó la evaluación con tomografía computarizada. La patología congénita más frecuente fue la estenosis - atresia de coana con un 53,8%, seguida de hendiduras craneofaciales con un 15.39%. En el 42.3% de los casos existió asociación con síndromes genéticos, patología neurológica, ocular e intestinal. El 69,23% de los pacientes recibió tratamiento clínico con lavados nasales, corticoides por vía nasal y presión positiva por cánula, mientras que el 30,77% se resolvió quirúrgicamente, siendo: 2 atresia unilateral de coana, 1 estenosis de fosa media, 4 hendiduras labio palatinas y 1 encefalocele. La mortalidad fue del 7,69%. **CONCLUSIÓN:**

#### CAMBios

<https://revistahcam.iess.gob.ec/index.php/cambios/issue/archive>

e-ISSN: 2661-6947

Semi-annual periodicity: continuous flow

Vol. 21 (1) Ene-Jun 2022

revista.hcam@iess.gob.ec

DOI: <https://doi.org/10.36015/cambios.v21.n1.2022.828>



This work is under an international licence Creative Commons Atribución-NoComercial

Las hipoplasias y las hendiduras son las patologías que predominaron, la nasofibroscopia flexible nasal es el examen diagnóstico de elección. El tratamiento clínico fue exitoso en el manejo inicial en el 69,23% de casos. La cirugía se realizó para la reparación de hendiduras faciales; siendo las hipoplasias o masas manejadas por abordaje endoscópico.

**Palabras clave:** Obstrucción Nasal; Endoscopia; Anomalías Congénitas; Atresia de las Coanas; Enfermedades Nasales; Recién Nacido.

## INTRODUCTION


Congenital nasal deformities are relatively rare, occurring in 1 in 5,000 to 40,000 live births<sup>1</sup>. These deformities also comprise a group of more infrequent anomalies with an embryopathogenic origins multiple and have a diverse clinical presentation. In addition, it is possible to find skin and subcutaneous involvement or they can also present as a morphological anomaly of the pyramid or in cases of bilateral obstruction, is a surgical emergency for the newborn.<sup>2</sup>

Nasal development begins in the third week of gestation in which it is characterized by the frontal, maxillary, and mandibular processes separated from each other by the stomodeum will form the primitive mouth. The nasal placodes derive from the ectoderm giving rise to the lateral and medial nasal processes that form the nasal cavity; which is separated from the oral cavity by the oronasal membrane<sup>3,4</sup>. The philtrum, columella, upper lip, nasal bone, and cartilage develop from the fusion of the medial nasal prominence<sup>5</sup>. Around the sixth week the development of the palate begins by the fusion of the medial maxillary process and the nasal septum comes from the frontal process<sup>5</sup>. In the same way as the medial pillars of the lesser lateral cartilages. From the lateral process develops the nasal bones, greater and lesser lateral cartilages; the nasal dorsum and glabella of the frontonasal prominence<sup>6</sup> and ends its progress until the eighth week. Figure 1.

For clinical diagnosis and its orientation, the mirror fog test or with a transnasal catheter to determine its patency. However, there are false positives and false negatives<sup>7</sup>. Endoscopic evaluation helps locate the site of obstruction with complete visualization of the fossa and should be complemented with imaging studies such as CT, which is one of the optimal options with excellent bone resolution; In addition, Magnetic Resonance (MR) has a better definition in soft tissues and is the most suitable for nasal masses by rule out intracranial invasion<sup>8</sup>.

Within the pathology of nasal obstruction, choanal atresia occurs in 1 in 5,000 to 9,000 births<sup>7</sup>: it is more frequent in the female sex, two thirds of the cases are unilateral, the side fluctuates depending on the series<sup>9</sup> one third of cases have bilateral presentation<sup>8</sup>.

There are four theories of pathogenesis, none of them universally accepted: 1.- Persistence of the oropharyngeal membrane of the foregut; 2.- Persistence or abnormal location of the mesoderm tissue that causes adherence in the region of the nasal choanas; 3.- Persistence of the Hochstetter's nasobuccal membrane; 4.- Abnormal migration of neural crest and mesoderm cells<sup>7</sup>. 30% of cases are bone and 70% are mixed (bone and membranous), being the exclusive membranous the rarest. Bilateral atresia manifests in newborns as respiratory distress, cyclical cyanosis, and marked difficulty swallowing; unilateral atresia presents with moderate nasal congestion.



**Figure 1: Embryological Craniofacial Developments<sup>5</sup>.**

Prominences: Mandibular = Cyan. Maxilla = Orange. Lateral Nasal = Pink. Nasal Medial = Green. Front = Yellow.

Source: Funamura JL, Tollefson TT. Congenital anomalies of the nose. *Facial Plastic Surgery*. 2016;32(2):133-41.

Obstructive nasal malformation alters the growth of newborns and infants depending on its severity. Also, symptoms can occur at birth or within the first few hours of life; includes tachypnea, apneic crisis and cyclic cyanosis that can be observed more frequently on bilateral choanal atresia, not being exclusive to itself<sup>7</sup>; also describes: swallowing disturbance, growth retardation, rhinorrhoea, nose deformity, and facial development disturbances<sup>8</sup>.

Choanal atresia can occur as part of a major class of defects such as CHARGE syndrome (ocular colobomas, heart defects, choanal atresia, restricted growth, genitourinary hypoplasia, and ear abnormalities); is the result of a mutation of the CHD7 marker on chromosome 8q12.2; it is detected in 65% to 70% of affected people<sup>7</sup>. Likewise, it is described that it may be associated with multiple craniofacial anomalies: Treacher Collins, Pierre Robin, Crouzon, cardiac anomalies, cleft lip and cleft palate, among others<sup>9</sup>.

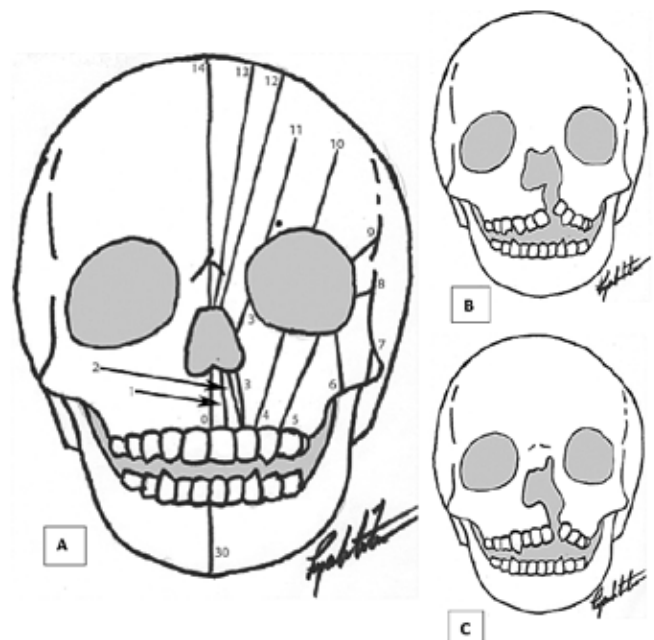
Middle fossa stenosis is a rare entity, secondary to a bilateral overgrowth of the midline of the nasal cavity, resulting in an excessive and unequal increase of the nasal septum on the nasal walls and folds<sup>8</sup>. It can be unilateral or bilateral. The diagnosis is confirmed by CT, the bone thickness of affected patients was 1.7 mm significantly lower than the control group of 3.2 mm ( $p < 0.0001$ )<sup>10</sup>. It is usually linked to other airway malformations: laryngomalacia, subglottic stenosis, or bronchial hyperreactivity; heart malformations and polycystic kidney<sup>11</sup>; Midfacial hypoplasia and fetal alcohol syndrome have also been reported<sup>12</sup>; few isolated cases have been reported<sup>13</sup>.

A deviated septum is a dislocation of the nasal quadrangular cartilage of the nasopalatine groove in newborns, its incidence varies between 0.6 to 31%<sup>14</sup> it can be purely cartilaginous or with posterior bone structures generally related to trauma during childbirth or compression and rotation forces applied to the maxilla during intrauterine growth<sup>8</sup>.

Congenital piriform nasal aperture stenosis (CNPAS) occurs in 1 in 25,000 births<sup>7</sup>. The piriform aperture is the space between the lateral nasal process of the maxilla, the horizontal process, and the superior and inferior nasal spine. CNPAS is caused by a defect in the formation of the primitive palate during embryogenesis or by an overgrowth of the lateral nasal process of the maxilla. The severity of the anatomic defect can range from mild to complete anterior atresia<sup>7</sup>. A diameter at the level of the inferior meatus is less than 11 mm on CT is diagnostic of this disease<sup>9</sup>. The associated anatomical anomaly is the presence of a maxillary medial central incisor, which is documented in up to 60% of cases, maxillary labial frenulum and maxillary hypoplasia; hypothalamic hamartoma and agenesis of the olfactory bulbs have been described, and up to 40% of patients have a disorder of the hypothalamic-pituitary axis<sup>12</sup>. Treatment varies from steroid drops for mild cases; dilations with urethral catheters for moderate cases; finally, sublabial surgical approach with drilling in the maxillary process in severe cases and having success with or without the use of stents<sup>7</sup>.

Tessier proposes the classification of craniofacial malformations, dividing them according to their complexity from 0 to 14. The first three affect the nose, as described in figure 2. The treatment of these fissures is surgical, the main objective being to reduce the malformations to stop correct growth and restore normal function of affected structures<sup>14</sup>.

Other less common reported anomalies are midline sinonasal masses that include encephalocele, dermoid cyst, gliomas, and nasolacrimal duct cyst, it occurs in an approximate 1 in 20,000 to 40,000 births. Encephalocele and glioma originate from defects in the base of the skull, while dermoid cysts derive from a defect in the anterior neuropore. These abnormalities have decreased with prenatal consumption of folic acid<sup>15</sup>. Pathophysiology they are formed during the development of the dura mater that extends inferior and posterior to the nasal frontal bone and before the alar cartilages that fill the prenasal space. Furthermore, these malformations occur because the dura does not recoil, and Figure 3 describes it. Other masses



**Figure 2. Classification of craniofacial malformations (\*)**

A: Numbered slits according to Tessier. B: Facial cleft 1. C: Facial cleft 2

Source: Winters, R. (2016). Tessier clefts and hypertelorism. *Facial Plastic Surgery Clinics of North America*, 24(4), 545–55.

are hemangioma, teratoma, and vascular malformations; they are most frequently associated with Ehlers-Danlos syndrome and frontonasal dysplasia. In Ecuador, at the Carlos Andrade Marín Specialty Hospital, an average of 3500 births take place every year.

The objective was to evaluate the etiology, associated comorbidities, mortality and management of congenital malformations of the nose in neonates at the Carlos Andrade Marín Specialty Hospital in Quito - Ecuador.

## MATERIALS AND METHODS

Observational prospective descriptive study. 103 medical records were reviewed with the codes of the International Classification of Diseases (ICD10): Q30.0, Q30.8, Q30.9, Q34.9, J34.2 that were accompanied by nasal obstruction, of which 26 were congenital malformations of the nose at the Carlos Andrade Marín Specialty Hospital in Quito - Ecuador between January 2009 to May 2022; in case of not meeting the criteria, the files were excluded. Tabulation and data analysis were performed in the Excel program. A modified Losee classification method was used<sup>6</sup>. That divides congenital nasal malformations into 4 types (Table 1)<sup>16</sup>. Follow-up time for all patients ranged from 6 months to 8 years with a mean of 3 years.

## RESULTS

Nasal deformities were present in 73.07% (19; 26) of the male sex. Nasal obstruction was symptom of consultation in all cases. The age of the first medical appointment was from 0 days to 1 year and the definitive diagnosis was made within the first 7

days after the evaluation by flexible nasofibroscopy. In 42.3% (11; 26) of the cases the evaluation was complemented with CT (Figure 4) and in 7.69% (2; 26) of the cases it was by MRI.

The most frequent congenital pathology was choanal atresia stenosis with 53.84% (14; 26), of these, 12 were bilateral stenoses and 2 unilateral atresias (Figure 5). They receive treatment with nasal lavage and inhaled corticosteroids, improving in the follow-up. One patient died due to comorbidities and endoscopic surgery was performed in unilateral atresias. The second pathology reported were craniofacial clefts and middle fossa stenosis with 15.38% each (4; 26). Table 2 describes the congenital pathologies according to the type of malformation.

In 42.3% (11; 26) of the cases there was an association of genetic syndrome, neurological, ocular and intestinal pathology. There were 16 pathologies in total, up to 3 pathologies in the same patient. Table 3.

69.23% (18; 26) received clinical treatment with nasal lavage, corticosteroids and positive pressure by nasal cannula, with which his respiration and saturation improved, thus remaining in the follow-up. 30.77% (8; 26) were resolved surgically, with 2 choanal atresias requiring repermeabilization: one middle fossa stenosis, 4 cleft lip and palate and 1 encephalocele by endoscopy. The mortality was 7.69% (2; 26) mortality related to the comorbidities.

## DISCUSSION

Nasal malformations are infrequent, when they occur can be become life-threatening, especially bilateral ones, and up to 50% of patients can develop signs of hypoxia and desaturation with repercussions on the vital prognosis.

This alterations occurred more frequently in male patients, identified in 73.07% of the cases in this study, similar to that described by Patel et al.<sup>12</sup>.

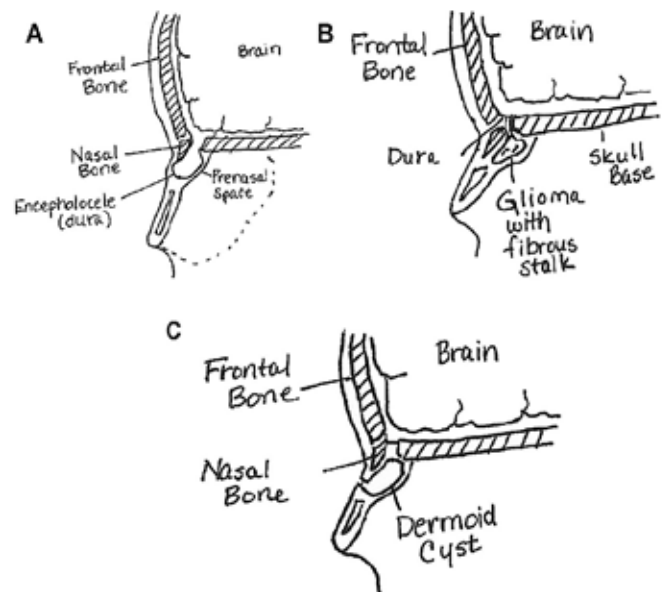
Nasal evaluation of a neonate begins with a complete clinical analysis. The physical evaluation must be complemented with a flexible nasofibroscopy to identify the side of stenosis and/or masses (Figure 3) as done in the study. CT and MR were used in 45.83% of the patients, we think that they were not performed in all patients, because they improved clinically during follow-up.

42.3% of patients presented associated malformations; this data is correlated with other studies that describes up to 50% of the cases. Thirty four percent of airway abnormalities have been described as tracheomalacia, laryngomalacia or subglottic stenosis and the 21% craniofacial anomalies which include CHARGE, Treacher Collins, Pfeiffer and Apert syndrome<sup>16</sup>. Graphic 1.

In the study a modified Losse classification was used. Type 1 was the most frequent presentation with 76.93.% and the Type 3 with 15.6%; similar data were described by Fijałkowska et al.<sup>1</sup>.

Choanal stenosis -atresia was the predominant pathology, the patients were clinically managed similar to Patel et al study<sup>12</sup>. Endoscopic surgical reparation is used when atresia is diagnosed and is done in successive stages: repermeabilization of the atresic plate,

enlargement of the bone framework and resection of the posterior portion of the vomer, covering the raw areas with endonasal vascularized flaps<sup>17</sup>; procedure realized to patients. On systematic reviews flaps have shown minor complications and best healing process on the formation of new choana compared to stents<sup>18,19</sup>. Nasal washes are indispensable for keeping permeability in the neochoana and avoid fibrosis or restenosis. Early surgery for bila-



**Figure 3.**

A: Encephalocele with dura extending into the prenasal space. B: Glioma with an extended stalk extending intracranially. C: Dermoid cyst in the prenasal space extending to the skin surface through a tract.

Source: Rajan, R. and Tunkel, DE (2018). Choanal atresia and other neonatal nasal anomalies. *Clinics in Perinatology*, 45(4), 751–767.

teral atresia has a lower risk of failure (24,8% vs 42.6%  $p=0.01$ ) delayed surgery. Nevertheless, if it is unilateral surgical intervention should differ until 6 months of age or more if is possible<sup>7</sup> since no benefits have been shown from performing it early<sup>20</sup>; same criteria was follow in the present study. Complementary mitomycin C indicated for reducing restenosis even though evidence about its effectiveness is still controversial<sup>21</sup>.

Middle fossa stenosis on Patel et al study<sup>12</sup> were the most frequent with the 38% of the cases and authors agree that the conservative management must be the initial<sup>13</sup>, this is based on the steroid drops usage and continuous positive airway pressure (CPAP) in cases where the obstruction does not improve; same criteria was applied on the patients of the study. Yet, if there is no improvement it is recommended a surgical intervention with nasal endoscopy and post stenotic dilation, this happened in one patient of the study. Some authors recommend endoscopic lateralization of the inferior turbinate and the others the use of stents<sup>8</sup>.

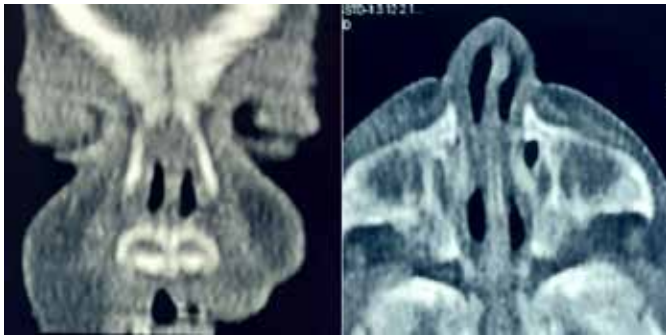
**Table 1. Classification scheme for congenital nasal anomalies.**

Grade	Category	Descriptions
I	Hypoplasia and atrophy	Atrophy or lack of development of skin, subcutaneous cellular tissue, muscle and bone
II	Hyperplasia and duplicity	Excess tissue, duplication of multiple parts or wholes
III	Clefts	Craniofacial clefts of the Tessier classification
IV	Neoplasms and vascular anomalies	Benign and malignant neoplasms, vascular anomalies

Source: Losee JE, Kirschner RE, Whitaker LA, Bartlett SP. Congenital nasal anomalies: a classification scheme. *Plast Reconstr Surg* 2004; 113(2):676–689

The patient who presented septal deviation was clinically managed, the surgical option had to be delayed as long as possible because of the cartilaginous and osseous structures considerably evolved during the first years. In addition, surgery is generally postponed until the scholar phase or even up to teenager age when symptoms persist<sup>13</sup>.

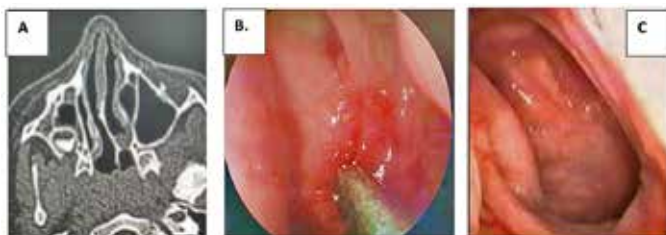Craniofacial clefts were the second most frequent pathology in



**Figure 4:** Middle fossa stenosis where a reduction in the middle fossa space is observed with an increase in the size of the nasal septum and nasal turbinate. Coronal and axial section. Source: Images taken by the authors.

the study. Tessier 1 shows one malformation that results in a complete cleft palate, it is noted hypoplastic maxillary creating a paradoxical choanal atresia<sup>22</sup>. On Tessier 2 it is noted a sinking of the nasal ala with a widened base and an ipsilateral lower pillar of the lateral side flattened<sup>22</sup>, all of them were operated as described in the medic literature<sup>14</sup>.

Encephalocele is a hernia of encephalic type through a defect in the base of the skull. Clinically presented as masses of blue



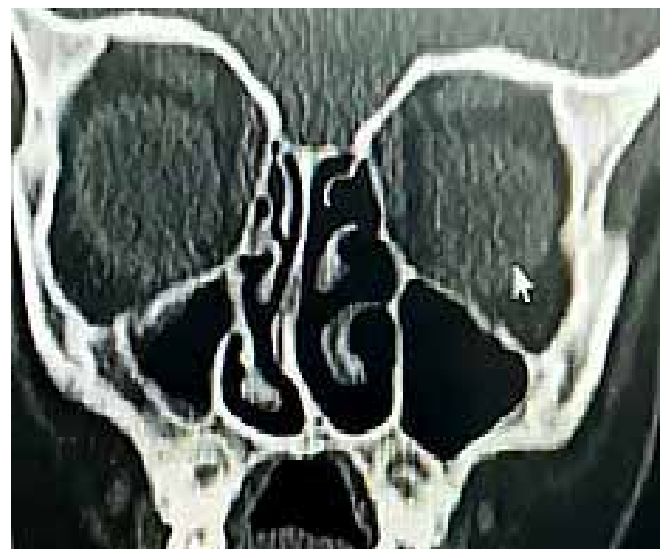**Figure 5.** A) Unilateral atresia of mixed choanal axial section. B) Atresia Endoscopic view. C) Normal endoscopic view. Source: Images taken by the authors.

**Table 2: Classification by nasal malformation**

	n	%
<b>Hypoplasia or atrophy</b>	<b>20</b>	<b>76.93</b>
Choanal atresia-stenosis	14	53.84
Nasal bone hypoplasia	1	3.84
Middle fossa stenosis	4	15.38
Septal Deviation	1	3.84
<b>Hyperplasia or duplications</b>	<b>1</b>	<b>3.84</b>
Bifid nose	1	3.8
<b>Craniofacial clefts</b>	<b>4</b>	<b>15.39</b>
Tessier clefts grade 1	2	7.69
Tessier clefts grade 2	1	3.84
Nasal wall cleft	1	3.84
<b>Nose Neoplasm</b>	<b>1</b>	<b>3.84</b>
Encephalocele	1	3.84
<b>Total</b>	<b>26</b>	<b>100</b>

Source. Investigation database. Elaborated by. The authors.

aspect, depressible pulsatile on the glabella or on the dorsum of the nose, they are transparent and they expand when the patients cry, force or when the jugular veins compress<sup>7</sup>. The treatment is surgically and closing the CSF fistula; it can be done by anterior



**Figure 6:** Coronal section of congenital septal displacement. Source: Images taken by the authors.

frontal craniotomy<sup>7</sup> or by transnasal endoscopic approach being safer and more efficient in pediatric patients<sup>15,23</sup>, like it was done in our patient; with a multidisciplinary approach (otorhinolaryngology and neurosurgery) the complications were reduced<sup>15</sup>. Emphasis should be placed on prenatal diagnosis with ultrasound or ultrafast MR specially on the early detection of nasal obstruction in case masses are detected (encephalocele and dacryocystocele); although, nasal cavity stenosis can't be diagnosed before birth by imaging methods<sup>13</sup>.

**CONCLUSIONS**

Hypoplasias and clefts are the predominant pathologies in this series, 42,3% had associated comorbidities. Nasal flexible nasofibroscope is the diagnostic test used. In 69,23% of patients clinical treatment was successful, surgery was performed to repair facial clefts; while hypoplasias or masses were managed by endoscopic approach. Mortality was 7.69%.

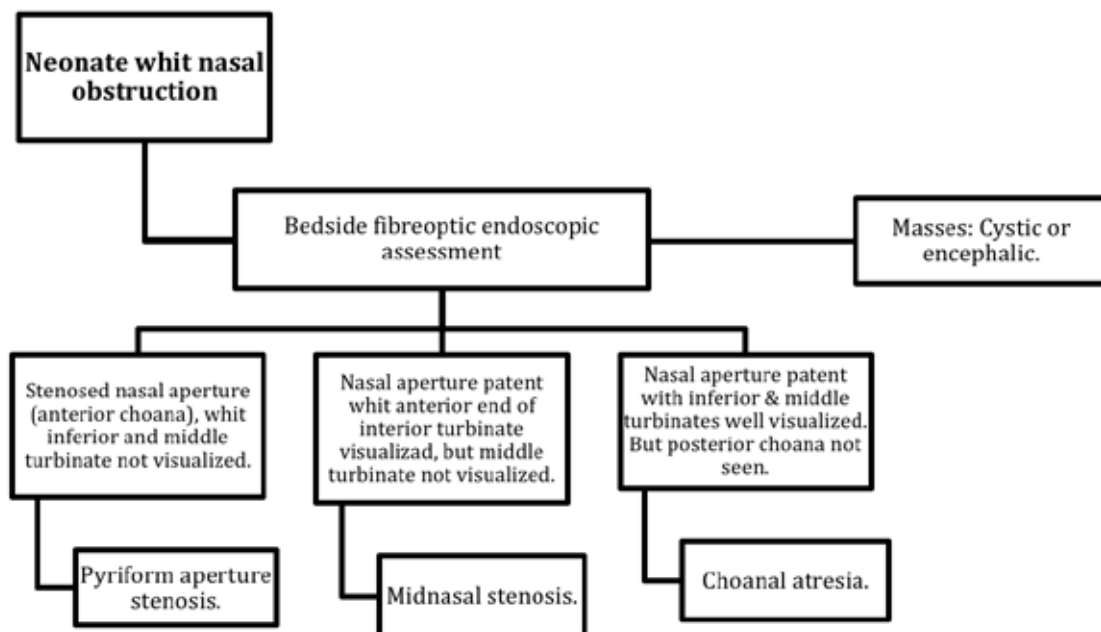
**RECOMMENDATIONS**

- It is recommended a proper clinical test if it is suspected any problem, supported by nasofibroscope, complemented by CT and MR.
- The treatments must be adequate to avoid the aggravation of the respiratory condition and even the death of the newborn.
- Regular meetings with the Department of Neonatology, Department of Maternal and Child, and Radiology as a multidisciplinary approach with the objective of ruling out suspicion or confirm diagnoses.
- Implement modules of congenital malformations in the Postgraduate Residence, to know the management of this type of pathologies.

**Table 3: Associated comorbidity**

	n	%		
HYPOPLASIA OR ATROPHY	8/20	40	Rubinstein-Taybi syndrome	1
			Charge syndrome	1
			Down's Syndrome	1
			Multiple malformations	3
			Hydranencephaly	1
			Congenital dacryostenosis	1
			Cyclopia	1
			Imperforate anus	2
			Zenker's diverticulum	1
			Tricuspid regurgitation	1
			Pentalogy of Fallot	1
			Unique Megaventricule	1
Low Set Ears	1			
HYPERPLASIA OR DUPLICATION	1/1	100	Agnesis of the corpus callosum (ACC)	
			Microphthalmia	
CRANIOFACIAL CLEFT	2/4	50	Imperforate anus	
			Binder syndrome	
			Colpocephaly	
NEOPLASM OF THE NOSE	0/1	0		
<b>TOTAL</b>				<b>16</b>

Source. Investigation database. Elaborated by. The authors.



Source: Syed K, Raja K, Kolethekkat A, Varghese A, al Abri R, Kurien M. Congenital midnasal stenosis: a novel technique for management. International Journal of Pediatric Otorhinolaryngology 2016; 87: 117–120.

Graphic 1. Endoscopic characteristics of nasal obstruction in newborns.

## ABBREVIATIONS

CNPAS: Congenital Nasal Pyriform Aperture Stenosis. CT: Computer Tomography. MR: Magnetic Resonance. ACC: Agenesis of the Corpus Callosum. CPAP: Continuous Positive Airway Pressure.

## AUTHORS CONTRIBUTION

CR, EE, MN, KF, TA: Conception and design of the work, Analysis and interpretation of data, Writing of the paper, Critical review of the paper, Approval of its final version and Justification of accountability.

## MATERIAL AND DATA DISPONIBILITY

Free-use bibliographic resources were used, in addition to the clinical history authorized by the patient. The information collected is available upon request to the main author.

## APPROVAL OF THE ETHICS COMMITTEE AND CONSENT TO PARTICIPATE

The study was approved by peers and by the “Comité de Ética de Investigación en Seres Humanos” CEISH/ Hospital Carlos Andrade Marin.

## CONSENT FOR PUBLICATION

The publication was approved by the “Comité de Política Editorial de la Revista Médica Científica CAMBIOS” of HECAM in minutes 001 dated June 08, 2022.

## FINANCING

Work made with the author’s resources.

## CONFLICT OF INTEREST

The authors reported having no conflict of personal, financial, intellectual, economic or corporate interest.

## ACKNOWLEDGEMENT

To all the teamwork that achieved a satisfactory completion of this article.

## BIBLIOGRAPHIC REFERENCES

- Fijałkowska, M., & Antoszewski, B. (2016). Classification of congenital nasal deformities: a proposal to amend the existing classification. *European Archives of Oto-Rhino-Laryngology*, 274(3), 1231–1235. Available from: <https://doi.org/10.1007/s00405-016-4195-y>
- Fayoux, P., Brouqsault, H., & Devisme, L. (2015). Anomalías congénitas de la nariz. *EMC - Otorrinolaringología*, 44(2), 1–12. Disponible en: [https://doi.org/10.1016/s1632-3475\(15\)70934-3](https://doi.org/10.1016/s1632-3475(15)70934-3)
- Günel, C., Başak, S., & Toskala, E. (2019). Congenital Malformations of the Nose and Paranasal Sinuses. *All Around the Nose*, 171–177. Available from: [https://doi.org/10.1007/978-3-030-21217-9\\_19](https://doi.org/10.1007/978-3-030-21217-9_19)
- Abdulkader, F., Lannigan, F. J., & Taha, M. (2020). Congenital Anomalies of the Nose. *Textbook of Clinical Otolaryngology*, 719–727. Available from: [https://doi.org/10.1007/978-3-030-54088-3\\_64](https://doi.org/10.1007/978-3-030-54088-3_64)
- Colson, T., Bertrand, B., Degardin, N., Bardot, J., & Casanova, D. (2017). Une malformation nasale congénitale non retrouvée dans la littérature : à propos de 5 cas. *Annales de Chirurgie Plastique Esthétique*, 62(1), 55–61. Available from: <https://doi.org/10.1016/j.anplas.2016.01.003>
- Funamura, J., & Tollefson, T. (2016). Congenital Anomalies of the Nose. *Facial Plastic Surgery*, 32(02), 133–141. Available from: <https://doi.org/10.1055/s-0036-1582231>
- Frank, S., & Schoem, S. R. (2022). Nasal Obstruction in the Infant. *Pediatric Clinics of North America*, 69(2), 287–300. Available from: <https://doi.org/10.1016/j.pcl.2021.12.002>
- Alvo, A., Villarroel, G., & Sedano, C. (2021). Neonatal nasal obstruction. *European Archives of Oto-Rhino-Laryngology*, 278(10), 3605–3611. Available from: <https://doi.org/10.1007/s00405-020-06546-y>
- Attya, H., Callaby, M., & Thevasagayam, R. (2021). Choanal atresia surgery: outcomes in 42 patients over 20 years and a review of the literature. *European Archives of Oto-Rhino-Laryngology*. Available from: <https://doi.org/10.1007/s00405-020-06506-6>
- Rajan, R., & Tunkel, D. E. (2018). Choanal Atresia and Other Neonatal Nasal Anomalies. *Clinics in Perinatology*, 45(4), 751–767. Available from: <https://doi.org/10.1016/j.clp.2018.07.011>
- Levi, L., Kornreich, L., Hilly, O., Raveh, E., & Gilony, D. (2020). Clinical and imaging evaluation of Congenital Midnasal Stenosis. *International Journal of Pediatric Otorhinolaryngology*, 132, 109918. Available from: <https://doi.org/10.1016/j.ijporl.2020.109918>
- Patel, V. A., & Carr, M. M. (2017). Congenital nasal obstruction in infants: A retrospective study and literature review. *International Journal of Pediatric Otorhinolaryngology*, 99, 78–84. Available from: <https://doi.org/10.1016/j.ijporl.2017.05.023>
- Galluzzi, F., Garavello, W., Dalfino, G., Castelnuovo, P., & Turri-Zanoni, M. (2021). Congenital bony nasal cavity stenosis: A review of current trends in diagnosis and treatment. *International Journal of Pediatric Otorhinolaryngology*, 144, 110670. Available from: <https://doi.org/10.1016/j.ijporl.2021.110670>
- Taib, B. G., Taib, A. G., Swift, A. C., & van Eeden, S. (2015). Cleft lip and palate: diagnosis and management. *British Journal of Hospital Medicine*, 76(10), 584–591. Available from: <https://doi.org/10.12968/hmed.2015.76.10.584>
- Van Wyhe, R., Chamata, E., & Hollier, L. (2016). Midline Craniofacial Masses in Children. *Seminars in Plastic Surgery*, 30(04), 176–180. Available from: <https://doi.org/10.1055/s-0036-1593482>
- Losee, J. E., Kirschner, R. E., Whitaker, L. A., & Bartlett, S. P. (2004). Congenital Nasal Anomalies: A Classification Scheme. *Plastic and Reconstructive Surgery*, 113(2), 676–689. Available from: <https://doi.org/10.1097/01.prs.0000101540.32533.ec>
- Bartel, R., Levorato, M., Adroher, M., Cardelus, S., Diaz, A., Lacima, J., Vazquez, C., Veneri, A., Wienberg, P., Claveria, M., & Haag, O. (2021). Performance of endoscopic repair with endonasal flaps for congenital choanal atresia. A systematic review. *Acta Otorrinolaringológica Española*, 72(1), 51–56. Available from: <https://doi.org/10.1016/j.otorri.2020.01.002>
- Alsubaie, H. M., Almosa, W. H., Al-Qahtani, A. S., &

- Margalani, O. (2021). Choanal Atresia Repair With Stents and Flaps: A Systematic Review Article. *Allergy & Rhinology*, 12, 215265672110580. Available from: <https://doi.org/10.1177/21526567211058052>
19. Gundle, L., Ojha, S., Hendry, J., & Rosen, H. (2021). Stenting versus stentless repair for bilateral choanal atresia: A systematic review of the literature. *International Journal of Pediatric Otorhinolaryngology*, 151, 110926. Available from: <https://doi.org/10.1016/j.ijporl.2021.110926>
20. Murray, S., Luo, L., Quimby, A., Barrowman, N., Vaccani, J. P., & Caulley, L. (2019). Immediate versus delayed surgery in congenital choanal atresia: A systematic review. *International Journal of Pediatric Otorhinolaryngology*, 119, 47–53. Available from: <https://doi.org/10.1016/j.ijporl.2019.01.001>
21. Luu, K., Tellez, P. A., & Chadha, N. K. (2021). The effectiveness of mitomycin C in Otolaryngology procedures: A systematic review. *Clinical Otolaryngology*, 47(1), 1–13. Available from: <https://doi.org/10.1111/coa.13839>
22. Winters, R. (2016). Tessier Clefts and Hypertelorism. *Facial Plastic Surgery Clinics of North America*, 24(4), 545–558. Available from: <https://doi.org/10.1016/j.fsc.2016.06.013>
23. Ma, J., Huang, Q., Li, X., Huang, D., Xian, J., Cui, S., Li, Y., & Zhou, B. (2015). Endoscopic transnasal repair of cerebrospinal fluid leaks with and without an encephalocele in pediatric patients: from infants to children. *Child's Nervous System*, 31(9), 1493–1498. Available from: <https://doi.org/10.1007/s00381-015-2746-y>